

ORIGINAL ARTICLE

Evaluation of tumor viability in Post radiation therapy pediatric brain tumors with ^{99m}Tc -glucoheptonate single photon emission computed tomography (SPECT)

Sukanta Barai[†], G. P. Bandopadhyaya[†], P. K. Julka[§], K. Naik[§], A. Haloi[‡], Arun Malhotra[†]

ABSTRACT Brain single photon emission computed tomography (SPECT) with ^{99m}Tc -glucoheptonate, a blood brain barrier imaging agent, is rapidly regaining interest after it has been shown that the uptake of tumor seeking agents like thallium, tetrofosmin, sestamibi and pertechnate by brain tumors is solely dependent on disruption of the blood brain barrier. Therefore, the use of ^{99m}Tc -glucoheptonate may yield the same diagnostic information as other agents such as the much more expensive ^{99m}Tc -sestamibi. The purpose of the study was to evaluate ^{99m}Tc -glucoheptonate as an imaging agent for recurrent primary brain tumors in children. **Methods:** Fifty-one patients aged 5-18 years were evaluated for tumor recurrence following radiotherapy for primary malignant brain tumors, using brain single photon emission computed tomographies (SPECT) with ^{99m}Tc -Glucoheptonate. Contrast enhanced computerized tomography (CT) of brain was performed in all patients within + 1 week of brain SPECT as a diagnostic standard and compared. **Results:** Recurrent tumors showed avid ^{99m}Tc -glucoheptonate concentration and a high ^{99m}Tc -glucoheptonate retention index (6.06 + 1.41) compared with post radiation gliosis, which showed no ^{99m}Tc -glucoheptonate concentration over the affected site and had a ^{99m}Tc -glucoheptonate retention index of 1.10 + 0.18 ($p=0.001$). ^{99m}Tc -glucoheptonate SPECT had a sensitivity of 79.48% and a specificity of 91.66% when compared with contrast-enhanced computed tomography as a gold standard. However, this technique did not show good performance in the differential diagnosis of lesions in posterior fossa. **Conclusion:** This study suggests that ^{99m}Tc -glucoheptonate brain SPECT can be used as a sensitive and specific diagnostic test to differentiate recurrent tumor from post radiation gliosis, with the exception of tumors located in posterior fossa. Further studies should address this limitation before definite protocols are established. **Key words:** Glucoheptonate, Fanbeam collimator, Glucoheptonate retention index, post radiation gliosis

* To whom correspondence should be addressed: Dr.Sukanta Barai, 197 Type 3 Quarters, AIIMS Residential Complex, A.V. Nagar, New Delhi. INDIA 110049. Fax-91-11-6862663 (please mention Dept. of Nuclear Medicine). E- Mail: danzig@rediffmail.com. Phone-91-9810302185

[†] Department of Nuclear Medicine

[§] Department of Radiotherapy

[‡] Department of Radiology

All India Institute of Medical Sciences. New Delhi, India

Survivors of brain tumors in childhood are at substantial risk of increased morbidity and late mortality. Five-year survivors of brain tumors are 13 times more likely to die than healthy age and sex matched controls. Tumor recurrence remains the single most common cause of late death, accounting for about 70% of the cases (1,2). Unfortunately, its clinical presentation can resemble that of post radiation necrosis

(3). If specific radiological features are not prominent, an elapse of time often occurs before investigations based on anatomical imaging allow to reach a conclusive diagnosis. This can be avoided by utilizing a functional imaging study. Functional imaging demonstrating blood flow and tissue metabolism can greatly help in differentiating a tumor, with increased blood flow and metabolism, from a post-radiation necrotic mass. The most often performed studies of this type for brain imaging are single photon emission tomography (SPECT) using thallium, sestamibi or tetrofosmin, and positron emission tomography using flurodeoxyglucose as a radiotracer. Tumoral lesions and normal brain tissue have different uptake properties for these tracers (4,5,6,7). The use of ^{99m}Tc -glucoheptonate (^{99m}Tc -GHA), an early brain SPECT tracer, has been disregarded over the years due to concerns that its accumulation in the tumors could be attributed to disruption of the blood-brain barrier caused by the tumor, rather than active extraction of the tracer in relation to tumor metabolism. Newly introduced tracers, such as ^{201}Tl in the late seventies and technetium-based thallium analogs in the mid eighties, were shown to accumulate in viable myocardium and became increasingly used for brain tumor imaging under the assumption that their uptake was independent of blood-brain barrier disruption. However, it has been suggested that disruption of the blood-brain barrier is a necessary condition for the uptake of any tumor seeking agent. Plain pertechnetate, whose uptake solely depends on disruption of the blood-brain barrier by the tumor, has been suggested to yield the same clinical information as the much more costly ^{99m}Tc -sestamibi (8,9). In this regard, there is a lack of studies testing the performance of ^{99m}Tc -GHA in pediatric patients with brain tumors. ^{99m}Tc -GHA is more economic than tetrofosmin, sestamibi or thallium, and is easily radiolabeled with technetium (^{99m}Tc) in a standard nuclear medicine pharmacy. The aim of the study was to assess if ^{99m}Tc -GHA can be used as a tumor-seeking substance for the diagnosis of recurrent brain tumors in childhood by functional imaging. We examined the performance of ^{99m}Tc -GHA in 51 patients with a previous diagnosis of pediatric brain tumors who were referred for evaluation of disease status by brain SPECT.

METHODS

Subjects

We recruited the patients for this study at the Nuclear Medicine Department, All India Institute of Medical Sciences, New Delhi, between 1998 and 2001. Eligible patients were up to 18 years old, had anatomopathological diagnosis of primary brain tumor

and received surgical treatment and postoperative radiotherapy. The patients were followed up at the Radiotherapy Cancer Clinic and referred to the Nuclear Medicine Department for brain imaging studies. Patients with undetermined tumor histology or who did not complete radiotherapy treatment were not included in the study. Out of 51 patients (55 male and 18 female) falling into the inclusion criteria and evaluated with ^{99m}Tc -GHA brain SPECT, 10 had medulloblastoma, 4 had ependymoma, one had dysgerminoma, one had atypical meningioma, one had invasive pituitary adenoma, 24 had low-grade glioma, 4 had glioblastoma multiforme (GBM) and 6 had anaplastic astrocytoma. For the purpose of this study, the 4 cases of GBM and 6 cases of anaplastic astrocytoma were grouped as high grade tumors, and tumor of all other histology were considered as low grade tumors. All studied subjects received a 4-38 month postoperative radiotherapy course, with a mean elapsed time of 12.6 months from the end of the treatment to the brain imaging study, and were clinically followed for a 10 - 35 month period (mean 18.2 months) after the brain SPECT. Brain contrast-enhanced computerized tomography (CT) was used as a gold standard for the diagnosis of tumor recurrence, and was performed in all subjects within +1week of the brain SPECT study. A repeated Brain SPECT using ^{99m}Tc -Tetrofosmin as tumor seeking agent was performed in patients with positive CT but negative ^{99m}Tc -GHA brain SPECT. Informed consent was taken from all patients' guardian.

^{99m}Tc -GHA study

To perform brain ^{99m}Tc -GHA SPECT, the patients were administered 370 - 740 MBq (10-20mCi) of in house prepared ^{99m}Tc -GHA i.v. For each individual, the dose was calculated as the body surface area divided by 1.73 and multiplied by the adult dose of 1,000 MBq. Brain SPECT images were acquired one hour post injection using a dual head single photon emission computed tomography system (Varicam from Elscint) fitted with fan beam collimator. Energy settings were 140 KeV with 20% energy window. A 128x128 matrix with 90 views every 4° for 25 seconds per view was obtained. Planar data were prefiltered prior to back projection and reconstruction with a two-dimensional Metz filter (cutoff=0.43 cm, P=30, Value of max=124, position of max=23, FWHM=100). Attenuation correction was done by Chang's method (10). Reconstructed images were displayed and analyzed using transverse, sagittal and coronal views.

Brain contrast-enhanced computerized tomography

Contrast-enhanced CT was performed 15 minutes after i.v. injection of a 2ml/kg-body weight contrast

Table 1. Tumor histology, location and approximate tumor size on CT of patients with false negative SPECT

Histology	Location	Size (in cm)
Atypical Meningioma	Brain stem	1.9x1.3x2.0
Low Grade Glioma	Pons	0.9x1.2x1.6
Low Grade Glioma	Pons	1.5x2.2x1.0
Glioblastoma Multiforme	Medulla	1.1x2.3x2.1
Ependymoma	4th Ventricle	1.3x0.8x1.2
Astrocytoma Grade 2	Cerebellum	2.3x2.9x3.1
Low Grade Glioma	Medulla	2.3x1.4x1.6
Dysgerminoma	Cerebellum	1.4x0.8x1.3

dose. Sensitivity to contrast was tested prior to injection. The region of interest was scanned with 3x3 mm axial cuts and 10x10 mm cuts were taken through the rest of the brain.

In-house Preparation of ^{99m}Tc -GHA

Glucuheptonate was prepared and labeled with ^{99m}Tc (Amersham Health Care Ltd., UK) by the following method. Five mg of glucuheptonate powder (Sigma Aldrich Corporation, Bangalore, India) were dissolved in 1 ml sterile water and 0.1 to 0.2 ml of stannous chloride (5mg stannous chloride in 1 ml 1N HCl) were added. The pH was adjusted to 6.5-7 by adding 1N NaOH. This solution was then passed through a filter (Millipore) and technetium pertechnetate was added. Instant thin layer chromatography (ITLC) was performed after every preparation of ^{99m}Tc -GHA to check the percentage of glucuheptonate molecules labeled with ^{99m}Tc (11). Any preparation with less than 98% labeling was discarded.

Data analysis

Two experienced nuclear medicine physicians blinded to the CT scan results evaluated the SPECT images independently. The images were interpreted as either showing or not showing evidence of tumor. Abnormally increased radiotracer uptake over the affected region was considered indicative of viable tumor. Absence of any abnormally increased tracer uptake over the site of the tumor was considered indicative of post radiotherapy gliosis. Preferential accumulation of the tumor seeking tracer in the tumor was defined as lesion-to-background ratio (glucuheptonate retention index). Two radiologists experienced in neuroradiology interpreted the CT findings independently and were blinded to the SPECT findings. Lesions were interpreted as post radiation gliosis if their Hounsfield unit values were close to cerebrospinal fluid density with no evidence of any mass effect, whereas lesions showing effacement of adjacent sulcal spaces (mass effect), with or without contrast enhancement, were reported as recurrent tumor.

Table 2. Validation parameters of ^{99m}Tc -GHA SPECT derived from this study

Parameter	^{99m}Tc -GHA Brain SPECT
Sensitivity	79.48%
Specificity	91.66%
Positive Predictive Value	96.87%
Negative Predictive Value	57.89%
Percentage of false neg. results	20.51%
Percentage of false pos. results	8.33%

^{99m}Tc -GHA index analysis

A region of interest (ROI) was drawn on the transverse slice showing the greatest tumor activity and an averaged pixel count was obtained. To obtain the background activity, a similar ROI was drawn on the opposite lobe or site. The ratio of the two values was obtained.

The ^{99m}Tc -GHA index was calculated as:

$$^{99m}\text{Tc} - \text{GHA Index} = \frac{\text{Average pixel count on Tumor ROI}}{\text{Average pixel count on contralateral ROI}}$$

Statistical analysis

^{99m}Tc -GHA index distributions in the high versus low tumor grade groups were compared using Mann-Whitney test. CT versus SPECT tumor diagnosis association was contrasted with Chi-square test. SPECT sensitivity and specificity were referenced to CT diagnosis as gold standard. A p value less than 0.05 was considered statistically significant.

RESULTS

Clinical follow-up and SPECT/CT evaluation after treatment of primary brain tumor

Brain SPECT revealed abnormally increased ^{99m}Tc -GHA uptake over the affected site in 32 of 51 patients, a scan feature consistent with viable tumor. The images were interpreted as either showing or not showing evidence of a tumor and there was no significant interobserver variability. Brain CT revealed tumor mass in 39 patients, including 31 patient who had positive SPECT (Figure 1 a,b). One patient with SPECT positive for recurrent tumor had a normal CT brain and was clinically asymptomatic, and was interpreted as a false positive SPECT study. Eight patients had mass lesions with features consistent with recurrent tumor in contrast-enhanced CT, and clinical course suggestive of recurrent tumor, but did not show any ^{99m}Tc -GHA concentration. These cases were interpreted as false negative SPECT studies (Figure 2 a,b). Repeated brain SPECT using ^{99m}Tc -Tetrofosmin, a better established brain tumor imaging agent, was performed in the eight patients where SPECT was normal but CT revealed a tumor mass (7). All of them had a normal ^{99m}Tc -

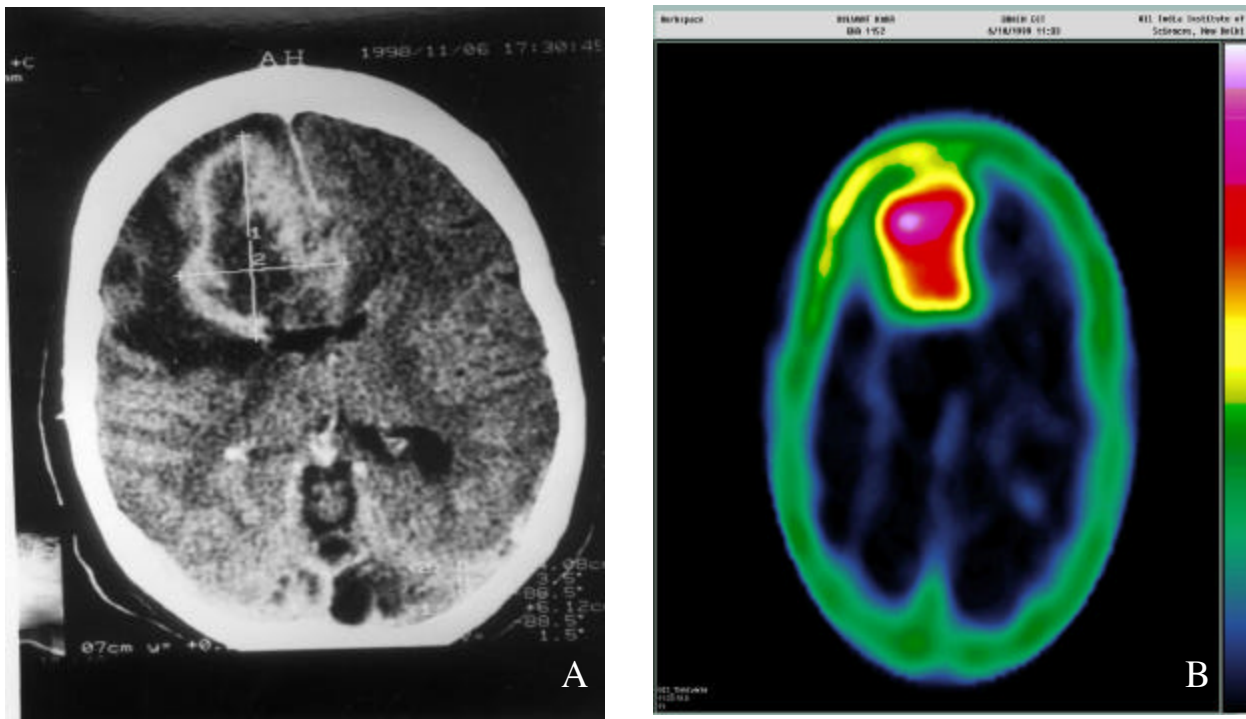


Figure 1: A. Coronal section of frontal glioblastoma multiforme showing contrast enhancement in CT. B. Corresponding SPECT slice of the same patient showing avid ^{99m}Tc -GHA concentration.

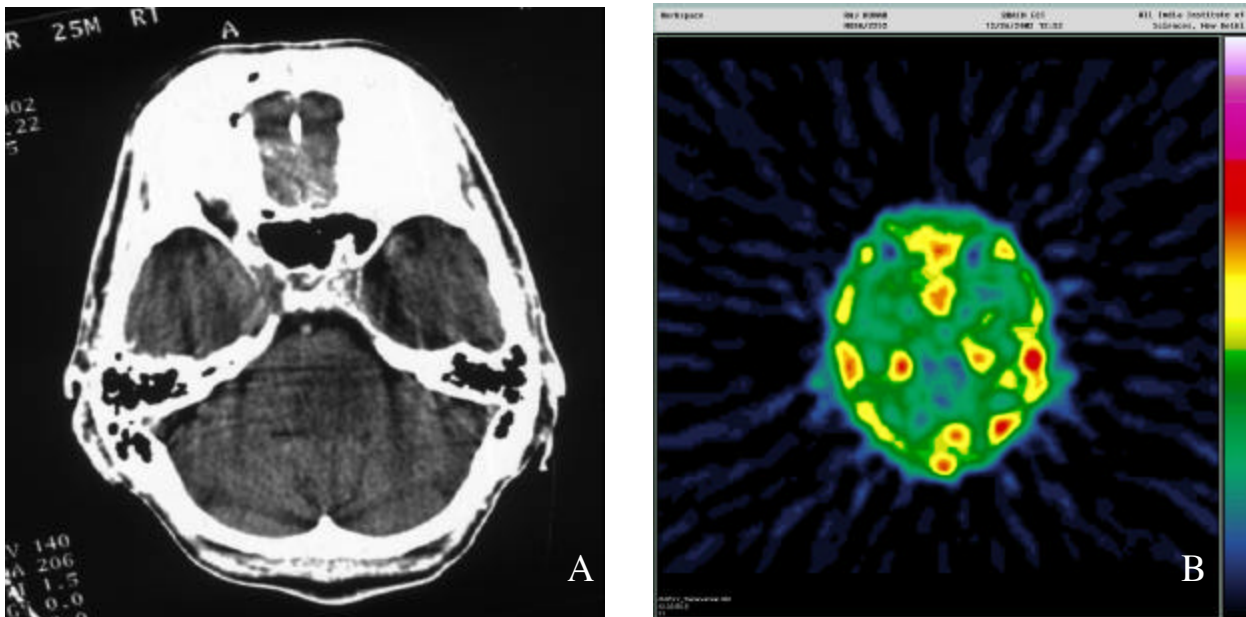


Figure 2 A. Coronal section of a low-grade glioma of medulla as seen on CT scan. B. A corresponding section from the SPECT study on the same patient shows no tracer concentration.

Tetrofosmin SPECT study. Table 1 shows the distribution, histology and approximate tumor size in the 8 patients who had positive brain CT and negative SPECT. Table 2 summarizes the validation parameters of ^{99m}Tc -GHA SPECT referenced to contrast-enhanced CT.

^{99m}Tc -GHA uptake in recurrent tumor versus gliosis

A higher ^{99m}Tc -GHA index was found in recurrent tumors (6.06 ± 1.41), as compared to 1.10 ± 0.18 in post radiation gliosis (Fig. 3). The difference was statistically significant ($p = 0.001$). All of the subjects

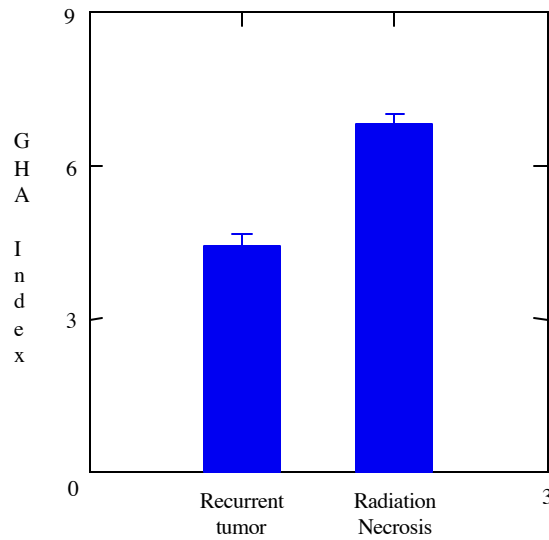


Figure 3. ^{99m}Tc -GHA uptake in recurrent and post radiation gliosis

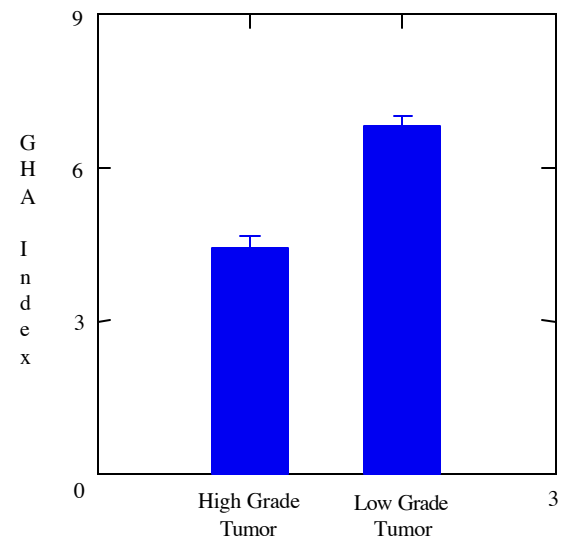


Figure 4. ^{99m}Tc -GHA uptake in high and low grade tumors

who developed post radiation gliosis had low grade tumors, and none of the cases with high grade tumors developed post radiation gliosis.

Relationship between tumor grade and ^{99m}Tc -GHA uptake

The mean ^{99m}Tc -GHA index was lower in high-grade tumors (glioblastoma multiforme and anaplastic astrocytoma; ^{99m}Tc -GHA index = 4.40 ± 0.79) compared with low-grade tumors (remaining tumor of all other histology; ^{99m}Tc -GHA index = 6.42 ± 0.83) (Fig. 4). The difference was statistically borderline ($p = 0.05$).

DISCUSSION

Functional imaging provides physiological information about body function. The main role of functional imaging in oncological practice is to determine whether a lesion observed in an anatomical study such as CT scan, ultrasound or MRI consists of tumor cells or is formed by fibrotic tissue only. The demonstration of increased tracer extraction and subsequent accumulation in the lesion indicates viability of the suspected tumor mass. Single photon emission computed tomography using suitable radiotracers is exquisitely sensitive in demonstrating viable tumor tissue at any anatomical location in the body.

In contrast-enhanced CT studies, tumors are considered viable if they show a focal mass-effect in the form of effacement of adjacent sulcal spaces with Hounsfield unit values equal to or higher than brain parenchyma, with or without enhancement using contrast. Conversely, lesions are interpreted as post-

radiation gliosis if there is evidence of focal volume loss with no enhancement with contrast. An increase in the size of the lesion after a temporal gap indicates a residual/recurrent tumor rather than focal gliosis. Compared with CT scans, ^{99m}Tc -GHA brain SPECT can identify viable tumoral tissue in a single study, tumor tracer retention being dependent upon an active uptake mechanism, thus eliminating the requirement of a temporal gap and a second study to establish a definite diagnosis (12). Pediatric brain tumors bear a high incidence of recurrence. Therefore, SPECT and positron emission tomography (PET) are routine investigations in oncological practice including pediatric brain tumor patients (1,4). In our unit we perform a SPECT study before the initiation of radiotherapy, after twelve weeks of completion of radiotherapy and then at six-month intervals. A final diagnosis of recurrent tumor or post radiation gliosis is established by combining the SPECT studies with the findings in CT scans and the clinical response to chemotherapy during the follow-up period.

The main observation in this study is the suitability of ^{99m}Tc -glucoheptonate as a potential radiotracer for the imaging of pediatric brain tumors. ^{99m}Tc -GHA shows intense physiological uptake in nasal mucosa, and large intracranial venous sinuses also retain a significant amount of radioactivity. Therefore, ^{99m}Tc -GHA brain SPECT may not be very suitable for the evaluation of tumors close to the nasal mucosa, like those situated in basifrontal lobe region, but it otherwise allows a good visualization of tumor margins (13). We observed a lower mean value for ^{99m}Tc -GHA index in high-grade tumors versus low-grade tumors. This finding may suggest a greater response to radiotherapy by more anaplastic tumors compared with low-grade tumors,

which would result in higher levels of tumor cell death or damage and, subsequently, in lower tracer uptake and retention.

Mechanism of Technetium-^{99m}Tc-Glucoheptonate Uptake

Glucoheptonate is a seven-carbon sugar. Tc-^{99m}glucoheptonate is a 1:2 Tc(v) complex with two glucoheptonate molecules combined with the metal (Technetium) through carboxyl and aliphahydroxyl groups (14). The mechanism of ^{99m}Tc-Glucoheptonate accumulation in brain tumors is not completely understood. The mechanism of uptake has been studied in proximal tubular cells in the kidney, and it seems to be dependent on cellular metabolism (15). In the present study, no ^{99m}Tc-GHA uptake was detected in normal brain tissue, suggesting that a breakdown or increased permeability at the blood-brain barrier (BBB) seems to be a condition necessary for ^{99m}Tc-GHA tumor uptake, similarly to any other brain tumor imaging agent (9). Leveille et al. suggested that glucoheptonate also acts as a substrate for the malignant tissue thus enhancing its uptake (16). The possibility of intracellular binding was also suggested by Tanasescu et al. (17).

The mechanism of ^{99m}Tc-Tetrofosmin accumulation in tumor

The mechanism of ^{99m}Tc-Tetrofosmin accumulation has been studied in myocardial cells, and it seems to be dependent on cellular metabolism because mitochondria take up the tracer through a process that is dependent on their membrane potential and their coupling state (i.e. their ability to couple oxidative phosphorylation) (18,19). In the present study no tetrofosmin uptake was observed in normal brain tissue, suggesting that the breakdown or an increased permeability of the blood brain barrier (BBB) seems to be a condition necessary for tetrofosmin uptake by the tumor. Nevertheless, studies using a tumor cell line showed that the uptake mechanism, intracellular distribution and washout kinetics of tetrofosmin are influenced by compounds that interfere with metabolic processes and that the mechanism by which the tracer enters the cells depends upon both cell membrane (Na⁺/K⁺ pump) and mitochondrial potential (20,21).

Recurrent tumor versus post-radiation gliosis

Establishing the cause of clinical deterioration in malignant glioma patients treated with high dose radiation therapy is critical because recurrent tumor may require repeated surgery or adjuvant therapy in order to improve the quality of life and survival rate, while radiation necrosis can be managed conservatively (22,23). Active ^{99m}Tc-GHA uptake by brain lesions

can allow to differentiate between tumor recurrence and post radiation changes. However, SPECT may fail to detect some tumoral lesions. In this study, all the tumors that escaped detection by SPECT were located in the posterior fossa compartment (Table 1). The posterior fossa is a compact anatomical space that allows relatively less expansion for the tumor to grow without compressing the neuronal structures. Thus, a tumor smaller than one cm can produce considerable clinical symptoms without being detected on SPECT, as the resolution of brain SPECT is around one cm. There are relatively more venous sinuses packed into a smaller space in the posterior fossa, and these sinuses frequently retain relevant amounts of the tracer, which sometimes may mask an adjacent tumor with less or equal intensity of tracer uptake. Another possibility is the existence of tumors that constitutively do not concentrate glucoheptonate or tetrofosmin. Blood-brain barrier endothelial cells may also be implicated in preventing tumors from concentrating a tracer because they express the multidrug resistance 1 gene, whose product is an adenosine triphosphatase membrane pump that extrudes a variety of toxins from the cells. ^{99m}Tc-tetrofosmin is one of these substrates. The inhibition of this multidrug resistance feature has been shown to delay the excretion of ^{99m}Tc-Tetrofosmin (24). Without inhibition, the pump prevents the tracer from reaching the interstitial space. It is possible that glucoheptonate is also a substrate for adenosine triphosphatase membrane pump.

CONCLUSIONS

In summary, this study shows that ^{99m}Tc-GHA brain SPECT can be used to differentiate recurrent primary tumors from post radiation gliosis in a pediatric population, with a sensitivity of 79.48% and a specificity of 91.66% in reference to contrast-enhanced CT. The low negative predictive value obtained in the tested population suggests that ^{99m}Tc-GHA SPECT would not be appropriate as a screening test on asymptomatic subjects, to discard tumor recurrence during follow-up. Tumors located in the posterior fossa encephalic compartment seem to be particularly conflictive for SPECT discrimination. In this case, ^{99m}Tc-GHA SPECT may not be an appropriate diagnostic test, and oncologists should interpret with caution a negative ^{99m}Tc-GHA brain SPECT in subjects with tumors located in posterior fossa.

Limitations of this study

Histopathological analysis of the recurrent lesions was not feasible because repeated surgery of primary brain tumors is rarely indicated in pediatric patients.

Therefore we have adopted contrast-enhanced CT as gold standard for this study.

Future Directions

A study with a larger sample size may help to evaluate the implications of the observed lower ^{99m}Tc -GHA uptake by more malignant tumors, and to better assess the application of brain SPECT to tumors in posterior fossa.

REFERENCES

1. Sklar CA. Childhood brain tumors. *J Pediatr Endocrinol Metab* 15 Suppl 2:669-73; 2002
2. Chan JL, Lee SW, Fraass BA, Normolle DP, Greenberg HS, Junck LR, Gebarski SS, Sandler HM. Survival and failure patterns of high grade gliomas after three-dimensional conformal radiotherapy. *J Clin Oncol* 20:1635-42; 2002
3. Shaw E, Arusell R, Scheithauer B, et al. Prospective randomized trial of low- versus high-dose radiation therapy in adults with supratentorial low-grade glioma: initial report of a North Central Cancer Treatment Group/Radiation Therapy Oncology Group/Eastern Cooperative Oncology Group study. *J Clin Oncol* 20: 2267-76; 2002
4. Utraiainen M, Metsahonkala L, Salmi TT, et al. Metabolic characterization of childhood brain tumors: comparison of 18F-fluorodeoxyglucose and 11C-methionine positron emission tomography. *Cancer* 95:1376-86; 2002
5. Kaplan WD, Takvorian T, Morris JH, Rumbaugh CL, Conndly BT, Atkins HL. Thallium-201 brain tumor imaging. A comparative study with pathological correlation. *Journal of Nuclear Medicine* 28: 47 - 52; 1987
6. Nishiyama Y, Yamamoto Y, Fukunaga K, Satoh K, Kunishio K, Ohkawa M. Comparison of ^{99m}Tc -MIBI with ^{201}Tl chloride SPET in patients with malignant brain tumours. *Nucl Med Commun* 22: 631-9; 2001
7. Choi JY, Kim SE, Shin HJ, Kim BT, Kim JH. Brain tumor imaging with ^{99m}Tc -tetrafosmin: comparison with ^{201}Tl , ^{99m}Tc -MIBI, and 18F-fluorodeoxyglucose. *J Neurooncol*; 46: 63-70; 2000
8. Soricelli A, Cuocolo A, Varrone A, et al. Technetium- 99m Tetrafosmin uptake in brain tumors by SPECT: Comparison with Thallium-201 imaging. *Journal of Nuclear Medicine* 39: 802-806; 1998
9. Staudenherz A, Fazeny B, Marosi C, et al. Does ^{99m}Tc -sestamibi in high-grade malignant brain tumors reflect blood-brain barrier damage only? *Neuroimage* 12: 109-11; 2000
10. Chang LT. A method for attenuation correction in radionuclide computed tomography. *IEEE Trans Nucl Sci NS* 25: 638-643
11. Pauwels EKJ, Feitsma RIJ. Radiochemical quality control of ^{99m}Tc -labeled radiopharmaceuticals. *Eur J Nucl Med* 2: 97; 1977
12. Dooms GC, Hecht S, Brant-Zawadzki M, et al. Brain radiation lesion: MR imaging. *Radiology* 158: 149-155; 1986
13. Waxman AD, Tanasescu D, Siemsen JK et al. Technetium- 99m glucoheptonate as a brain screening agent. *Journal of Nuclear Medicine* 17; 345-348; 1977
14. Roland Muller-surr. Radiopharmaceuticals: their intrarenal handling and localization. In: *Nuclear medicine in clinical diagnosis and treatment Vol. 1*. New York, US Churchill Livingstone, 1994
15. Lee HB, Blaufox MD. Mechanism of renal concentration of technetium- 99m glucoheptonate. *Journal of Nuclear Medicine* 26: 1308-1313; 1985
16. Levielle J, Pision C, Karakand Y et al. Technetium- 99m glucoheptonate in brain tumor detection: an important advance in radiotracer technique. *Journal of Nuclear Medicine* 18: 957-961; 1977
17. Tanasescu D, Wolfstein R, Waxman AD. Technetium- 99m glucoheptonate as a brain scanning agent. *Editorial Journal of Nuclear Medicine* 18: 1037-1038; 1977
18. Platts EA, North TL, Pickett RD, Kelly JD. Mechanism of uptake of technetium tetrafosmin I: uptake into isolated adult rat ventricular myocyte and subcellular localization. *Journal of Nuclear Cardiology* 2: 317-316; 1995
19. Younes A, Singled JA, Maublant J, Platts E, Pickett R, Veyre A. Mechanism of uptake of technetium-tetrafosmin, II: uptake into isolated adult rat heart mitochondria. *Journal of Nuclear Cardiology* 2: 317-316; 1995
20. Perek N, Prevot N, Koumanov F, Frere D, Sabido O, Beauchesne P, Dubois F. Involvement of the glutathione S-conjugate compounds and the MRP protein in Tc-^{99m} tetrafosmin and Tc-^{99m} -sestamibi uptake in glioma cell lines. *Nucl Med Biol* 27: 299-307; 2000
21. Arbab AS, Koizumi K, Toyama K, Arai T. Uptake of ^{99m}Tc -tetrafosmin, technetium- 99m -MIBI and thallium-201 in a tumor cell line. *Journal of Nuclear Medicine* 37: 1551-1556; 1996
22. Kristiansen K, Hagen S, Kollevolt T, et al. Combined modality therapy of operated astrocytoma grade 3 and 4: Confirmation of the value of post operative irradiation and lack of potentiation of Bleomycin on survival time: a prospective multicenter trial of the Scandinavian Glioblastoma study group. *Cancer* 47: 649; 1981
23. Yamamoto M, Oshiro S, Tsugu H, et al. Treatment of recurrent malignant supratentorial astrocytomas with carboplatin and etoposide combined with recombinant mutant human tumor necrosis factor-alpha. *Anticancer Res* 22: 2447-53; 2002
24. Bae KT, Pivnicka-Worms D. Pharmacokinetic modeling of multidrug resistance P-glycoprotein transport of gamma-emitting substrates. *Q J Nucl Med Jun* 41:101-10; 1997

Dr. Sukanta Barai is a post graduate trainee pursuing post MD experience course in the Department of Nuclear medicine at All India Institute of Medical Sciences .New Delhi. India. He holds a Bachelors degree in Medicine from Rajasthan University India and recently has completed his residency in Nuclear Medicine from All India Institute of Medical Sciences .New Delhi. His research interests include imaging of brain tumor and developing new radiopharmaceuticals for tumor imaging. **Dr.G.P.Bandopadhyaya** is Additional Professor and chief of Radiopharmacy unit. **Dr.P.K.Julka** is Professor in Department of Radiotherapy, **Dr. K.Naik** is senior resident in the Department of Radiotherapy, **Dr. A.Haloi** is senior resident in the Department of Radiology and **Dr.Arun Malhotra** is Professor and Head of Department of Nuclear medicine at All India Institute of Medical Sciences, New Delhi. India