

CASE REPORT

A Rare Variant of a Common Nodule

Nancy Xi*, Dalal Assaad, David N. Adam

INTRODUCTION

Dermatofibromas, or benign cutaneous fibrous histiocytomas, are relatively common, slow growing, benign tumours composed of a mixture of fibroblastic and histiocytic cells. They usually manifest on the extremities (legs > arms > trunk) during early or mid adult life with a male to female ratio of 1:2 (1). In most cases, the etiology of the tumour is unknown, but is generally hypothesized to be a late histiocytic reaction to local trauma (insect bites, viral warts) or to an inflammatory condition (atopic dermatitis, lichen sclerosis, psoriasis) (1).

These lesions appear gradually over several months, may persist without change in size for years, and can regress spontaneously. They often present as asymptomatic solitary nodules, between 3 to 10mm in size, with ill defined borders that fade to normal skin. The overlying skin is red or red-brown in colour, but occasionally may appear black. The dimple sign, where a central depression within the lesion is elicited upon compression along its margin, is often conducted to aid in the diagnosis of dermatofibromata. However, it is important to keep in mind that this clinical finding is not specific for dermatofibromas, and can be elicited in various other papulonodular lesions, including blue nevi, pilar cysts, and Kaposi sarcoma (2). Because of the benign nature of this lesion, no treatment is necessary unless there is recurrent trauma irritating it (1). Excision and cryotherapy can be used in these circumstances, with cryotherapy as the preferred method due to its more cosmetically acceptable results. The recurrence rate is approximately 10% following conservative therapy, with lesions located in deep soft tissue at greatest risk of recurrence (5).

THE CASE

A 59 year old Caucasian man presented with a 30 year history of a solitary, slowly growing tumor on his left lower leg. The referring physician had been treating him with betamethasone valerate 0.01%. The lesion had not demonstrated any bleeding, pruritus, or recent growth. The patient was otherwise in good health and denied any other symptoms. He did not recall local trauma in the area and denied a past history of any autoimmune conditions. Examination of the skin revealed a firm, well demarcated, yellowish to skin coloured plaque measuring 4.5 x 3.2 cm in diameter. Punch biopsies were taken from the center and periphery of the lesion (Figure 1).

Histologic examination revealed marked acanthosis and hyperkeratosis of the epidermis. Evident within the dermis layer was a fibrohistiocytic tumour, characterized by foamy, spindle shaped cells scattered between dense collagen bundles (Figure 2,3). The betamethasone valerate was discontinued and no other medication course was initiated. Instead, the patient was closely monitored.

DISCUSSION

Although dermatofibromas are common, the xanthomatous variant (XDF) is extremely rare (3). While other subtypes exhibit various numbers of lipid-containing tumor cells with a foamy or xanthomatous appearance, this variant is characterized by xanthomatous cells that predominate within a fibrous stroma of collagen bundles (4). The most important diagnostic aspect with this particular subtype is to distinguish it from other more invasive forms of fibrohistiocytic tumours, such as dermatofibrosarcoma protuberans (DFSP), malignant fibrous histiocytoma (MFH), and atypical fibroxanthoma (AFX) (5). Positive immunohistochemical staining for Factor XIIIa, present in normal populations of dermal dendrocytes, can be used to distinguish XDF from DFSP and MFH (6). However, a positive result is not specific for dermatofibromas, as AFX and other inflammatory conditions

*To whom correspondence should be addressed:

Nancy Xi
nancy.xi@utoronto.ca

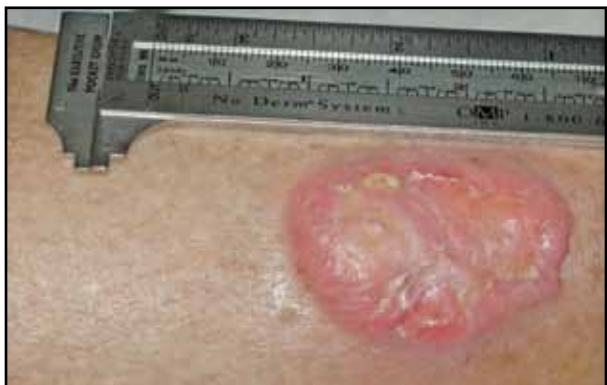

Figure 1: Gross view of a xanthomatous dermatofibroma found on this patient's left lower leg, measuring 4.5 x 3.2 cm in diameter.

also can demonstrate XIIIa positivity (6). Thus, histologic examination must be used to further distinguish XDF from AFX. The benign nature of XDF is apparent histologically, as the variant is characterized by well differentiated cells with little pleomorphism and mitotic activity, in contrast to the high degree of mitotic activity and atypical mitosis observed in AFX (3,7). From a clinical standpoint, the ability to distinguish xanthomatous dermatofibroma is very important, as an incorrect interpretation could result in inappropriate treatment.

REFERENCES

1. Freedberg IM: Dermatofibroma; in Freedberg IM, Eisen AZ, Wolf K et al (eds): Fitzpatrick's Dermatology in General Medicine, v 1, ed 6. Toronto, McGraw Hill, 2003, pp 995-996.
2. Wolff K: Dermatofibroma; in Wolff K, Johnson RA (eds): Fitzpatrick's Colour Atlas and Synopsis of Clinical Dermatology. Ed 6. Toronto, McGraw Hill, 2009, pp 224-226.
3. Ackerman AB: Xanthomatous dermatofibroma vs. xanthomatous malignant fibrous histiocytoma; in Ackerman AB, Briggs PL, Bravo F (eds): Differential Diagnosis in Dermatopathology III. Philadelphia, Lea & Febiger, 1992, pp 54-57.
4. Gonzalez S, Duarte I: Benign fibrous histiocytoma of the Skin: a morphologic study of 290 cases. *Pathol Res Pract* 1982; 174(4): 379-391.
5. Enzinger FM, Weiss SW: Benign fibrohistiocytic tumours; in Enzinger FM, Weiss SW (eds): *Soft Tissue Tumours*, ed 2. St. Louis, Mosby, 1988, pp 223-251.
6. Cerio R, Spaul J, Oliver GF et al: A study of factor XIIIa and MAC 387 immunolabeling in normal and pathological skin. *Am J Dermatopathol* 1990; 12: 221-233.
7. Leyva WH, Santa Cruz DJ: Atypical cutaneous fibrous histiocytoma. *Am J Dermatopathol* 1986; 8: 467-471.

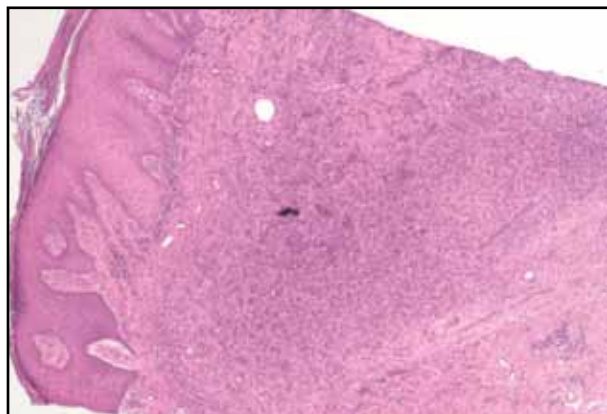


Figure 2: H and E stain of biopsy from centre of the lesion. Low power magnification view. Note the marked acanthosis and hyperkeratosis of the epidermis.

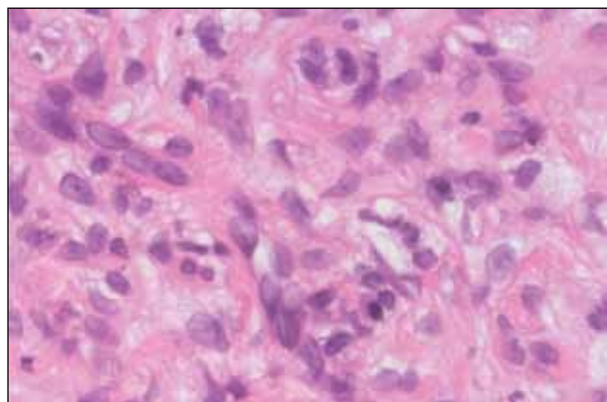


Figure 3: H and E stain of biopsy from centre of the lesion. High power magnification view. Evident are the foamy, spindle shaped cells, scattered between dense collagen bundles.

Nancy Xi, B.H.Sc, (MD 2011), is currently a third year medical student at the University of Toronto with an interest in dermatology and internal medicine.

Dalal Assaad, MD, FRCPC, is an Assistant Professor of Dermatology at the University of Toronto.

David N. Adam, MD, FRCPC, is a Lecturer in the Department of Medicine, Division of Dermatology at the University of Toronto. He is also a consultant at St. Michael's Hospital.